

Sandhill Veterinary Services

Game Bird, Poultry and Pigeon care

RICHARD T. BYAS B.Vet. Med., M.R.C.V.S.

Spring 2013

WELCOME to our spring newsletter for grouse clients with our invitation to attend our practice meeting at Topcliffe Village Hall on 12th February on the reverse.



Office Opening Times:

Monday-Friday
8.30am - 5.00pm

Saturday
9.00am - 12.00noon

All other times by
appointment only

**14 Long Street
Topcliffe
Thirsk**

**North Yorkshire
YO7 3RW**

Tel:

01845 578710

Fax:

01845 577685

e-mail:

rtb@sandhillvet.co.uk

Web:

www.sandhillvet.co.uk

Grouse Newsletter 2013

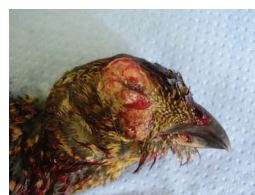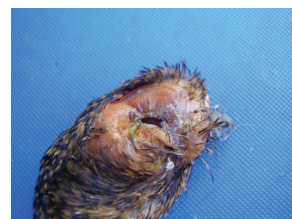
AN INCREASE IN DISEASE SEEN ON THE MOORS IN 2012

Early in 2012 there was a report of suspect Mycoplasmosis affecting grouse in Teesdale and these reports were carried in the national shooting press. However laboratory testing of samples at AHVLA Lasswade showed that the disease suspected as being caused by Mycoplasmosis, which is a bacterial infection, was in fact due to a parasitic infection caused by the Cryptosporidium protozoon. Both diseases result in swelling of the head and differentiation is only possible by laboratory testing.

Following the reported disease outbreaks in Teesdale the practice had a number of cases of grouse with swollen heads submitted for examination. In all cases a full post mortem examination was performed on the birds to determine if any other conditions were also present after which the heads were submitted to AHVLA Lasswade for histology and culture. Although the primary interest in all cases was the facial swelling, secondary conditions seen in the birds included high worm counts and high levels of coccidiosis. Three distinct causes of head swelling were detected in the birds we examined:

1) Cryptosporidium infection:

This was the most common condition found after histological examination at AHVLA Lasswade. Our findings extended the known range of infection south of Teesdale but not enough work has yet been done to determine whether the disease is in fact spreading or if it is widespread at low levels on many moors and because of the publicity more birds are being submitted for examination.



2) Fowl Pox infection:

A single bird with a swollen head was submitted which showed to be fowl pox infection on histological examination. Fowl pox is carried by a wide range of both domestic and wild birds but we have not been able to find a reference to it being diagnosed before in grouse.

3) Trauma:

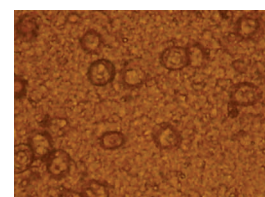
There can be swelling of the head in shot bird due to trauma. The trauma may mask any ante-mortem swelling due to disease and the only way to be sure of the clinical status of the birds is histological examination. A number of such birds were submitted to the practice

Mycoplasmosis:

All the birds submitted to AHVLA Lasswade had samples taken and submitted to AHVLA Weybridge to culture for Mycoplasma. Although most of the birds carried Mycoplasma bacteria, they were not the types of Mycoplasma known to cause clinical disease and so were classed as 'symbiotic' i.e. living with the birds but having no adverse clinical effects.

Coccidiosis:

High levels of coccidiosis were detected in young birds that were not growing well in the early and mid rearing period and the levels of coccidiosis suggested that they were a contributory factor in the poor performance of the birds.



See overleaf for your practice meeting invitation



High Strength Grit (10mg per gram)*

Available *exclusively* from Sandhill Veterinary Services
(in collaboration with Mr Douglas Wise MRCVS)

- available in 16kg packs
- each pack sufficient to treat 1000 acres
- for use up to mid-March on moors with high worm counts

* only available on veterinary prescription.



PRICE LIST 2013

Services:

| | |
|---|-------|
| Post-mortem | 28.00 |
| Bacterial culture | 6.50 |
| Coccidial oocyst / worm egg count | 6.50 |
| Trichostrongylus worm count (Grouse) | 12.50 |
| Medicated foodstuff prescription | 8.50 |

All prices quoted are exclusive of VAT

All prices quoted are subject to alteration
without notice.

SANDHILL VETERINARY SERVICES
Richard T. Byas B. Vet. Med., M.R.C.V.S